Appendix, to be or not to be - Differential Diagnosis of right lower quadrant abdominal pain

e-Poster: EE-161

Congress: ESGAR 2015

Type: Educational Exhibit

Topic: Diagnostic / Other - Acute and Post-Traumatic Abdomen

Authors: M. Magalhães, D.R. Andrade, P. Gomes, F. Caseiro Alves; Coimbra/PT

1. Learning Objectives

· To make a differential diagnosis list with the main diseases presenting with right lower quadrant pain (RLQP), besides acute appendicitis;

· To demonstrate the main imaging findings of the various conditions presenting with RLQP.

2. Background

Right lower quadrant abdominal pain (RLQP) is one of the most frequent causes of a patient going to the emergency department and appendicitis is the most common condition requiring surgery in patients with abdominal pain. However, appendicitis can mimic several diseases and many disorders are initially incorrectly diagnosed as appendicitis.

A misdiagnosis can lead to a delayed treatment in patients with appendicitis or may result in a normal appendix removal in patients with other causes of RLQP. Many of these alternative disorders are self-limiting or can initially be managed with medical therapy.

Imaging techniques, specifically sonography and CT, had evolved to play a fundamental role in this setting, being essential for the radiologist to be familiarized with imaging findings of numerous differential considerations.

3. Imaging Findings/Procedure Details

Appendicitis

The appendix is a blind-ending tubular structure that arises from the posteromedial aspect of the cecum, approximately 3 cm below the ileocecal valve, with a free mobile ending, which accounts for its variable location in the abdomino- pelvic cavity. Relative to the cecum, the appendix is most commonly either retrocecal (about two- thirds of patients) or inferomedial (about one- third of patients). The appendix can have a retroileal or preileal location or extend to the pelvis. Its free end sometimes can extend into the subhepatic space.

Appendicitis remains the most common indication for emergent abdominal surgery. The diagnosis of acute appendicitis is usually made on the basis of patient's clinical history in conjunction with physical examination and laboratory studies. Because the surgical aim is to operate early—before appendiceal rupture and peritonitis develop—patients who present with typical findings undergo immediate surgery without radiologic evaluation. However, in atypical cases (35%–45% of patients) diagnosis can be difficult on the basis of clinical grounds alone, and it is in this group in whom imaging is most helpful.

The sensitivity of US ranges between 44% and 98%, and its specificity ranges between 47% and 95%, whereas the sensitivity and specificity of CT range between 87% and 100% and 89% and 99%, respectively.

The normal appendix has a maximum outer diameter of 6 mm, is surrounded by homogeneous noninflamed fat, is compressible on sonography and often is totally collapsed or partially filled with fluid or air. The normal appendiceal wall measures less than 1–2 mm in thickness.

<u>Imaging Findings (sonography and CT):</u>

When inflamed, there are some imaging criteria that allows the correct diagnosis. The most important signs (Fig 1 and 2):

· 6 mm of maximum diameter

· Parietal thickening

· periappendicular fat stranding on CT, which is hyperechoic on sonography

- Other findings that are often present and support the diagnosis:

· Presence of an appendicolith

· Periappendiceal fluid collection

· Cecal apical thickening (Fig 3)

· Incompressible appendix on sonography

· Hypervascularity of the appendix wall on color Doppler sonography

· Thickened and enhancing wall on CT

A focal defect in the wall of the inflamed appendix, an appendicolith outside the appendix, a periappendiceal fluid collection, or extraluminal air near the appendix indicates perforation of the appendix (Fig.4). In such cases, the appendix may be difficult to identify. Presence of severe fat stranding in the right lower quadrant, in the absence of substantial cecal or ileal thickening suggests the possibility of appendicitis.

One of the most important imaging criteria in the evaluation of appendicitis is the outer diameter of the appendix. Although a threshold diameter of 6 mm is most commonly used for diagnosing appendicitis, a high percentage (24%– 42%) of the population has an appendiceal diameter greater than 6 mm. Therefore, in the absence of any other CT signs of appendicitis, a threshold diameter of 6 mm is not a reliable indicator.

The diagnosis from CT findings is straightforward if the appendix is easily visualized.

Fig. 1

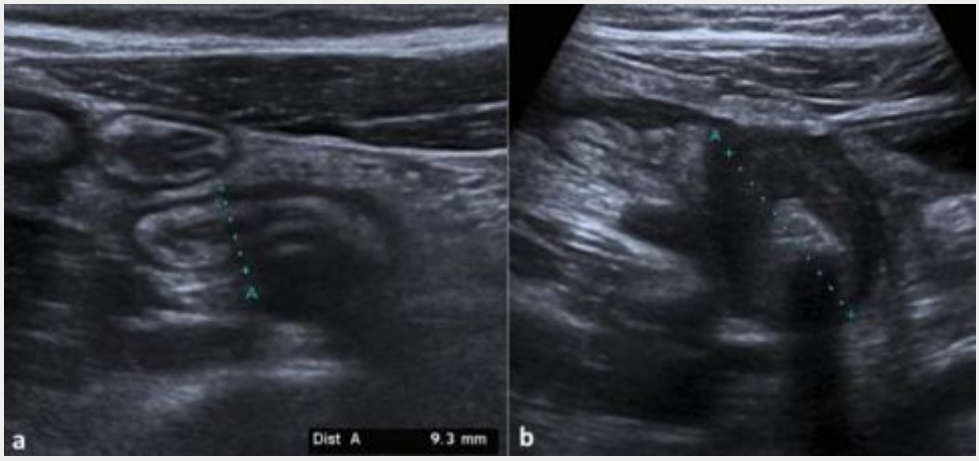

US images of an inflammed appendix. a) the appendix is distended, with parietal thickening and periappendicular fat is hyperechoic; b) intraluminal appendicolith.

Fig. 2

Thickened appendix with an intraluminal appendicolith

Fig. 3

Cecal thickening in a patient with appendicitis.

Fig. 4

CT showing a perforated appendix – a distended and thickened appendix, with periappendicular fat stranding and a collection surrounding its end.

Mesenteric adenitis

It is a benign self-limiting inflammation of right-sided mesenteric lymph nodes, without an identifiable acute inflammatory condition, without an identifiable underlying inflammatory process. It is the second most common cause of RLQP after appendicitis, accounting for 2–14% of the discharge diagnoses in patients with a clinical suspicion of appendicitis. It occurs more commonly in children than adults. As mesenteric adenitis usually presents in the young, ultrasound is often the investigation of choice. CT is usually reserved for older patients, if needed at all.

Imaging Findings (sonography and CT):

· Cluster (more than three) of enlarged mesenteric lymph nodes in the right lower quadrant (short-axis diameter of at least 5 mm);

· Normal appendix; no other identifiable inflammatory condition.

Fig. 5

Mesenteric adenitis - CT of a young patient with RLQP showing severel mesenteric enlarged mesenteric lymph nodes, with no other identifiable inflammatory condition.

Crohn Disease

Crohn disease can manifest anywhere in the gastrointestinal tract, but the ileocecal region is most commonly affected by the disease. Although most patients experience chronic symptom, acute exacerbations or complications may lead to acute abdominal pain. Moreover, many cases of Crohn disease (up to one-third of patients with ileocecal Crohn's disease) are diagnosed during work-up of acute RLQP.

Imaging Findings (acute phase):

· Parietal thickening of terminal ileum, often predominantly the submucosal layer (submucosal edema) and mucosal and serosa hyperenhancement – target sign (Fig.6);

· Engorgement of vasa recta that penetrate the bowel wall (comb sign)

· Reactive mesenteric lymph nodes may be present;

· Inflammatory changes of the surrounding fat (hyperechoic in sonography and fat stranding on CT).

The most common enteric complications associated with Crohn disease are small bowel strictures causing obstruction, fistulas, and abscesses, and are readily diagnosed with CT. An abscess can be confined to the bowel wall and pericolic fat or involve adjacent structures such as the bladder, psoas muscle, and pelvic sidewall (Fig. 7). Multiplanar reformation is particularly helpful in characterizing fistulous tracts, which include enterovesical, enterocutaneous, perianal, and rectovaginal fistulas.

Fig. 6

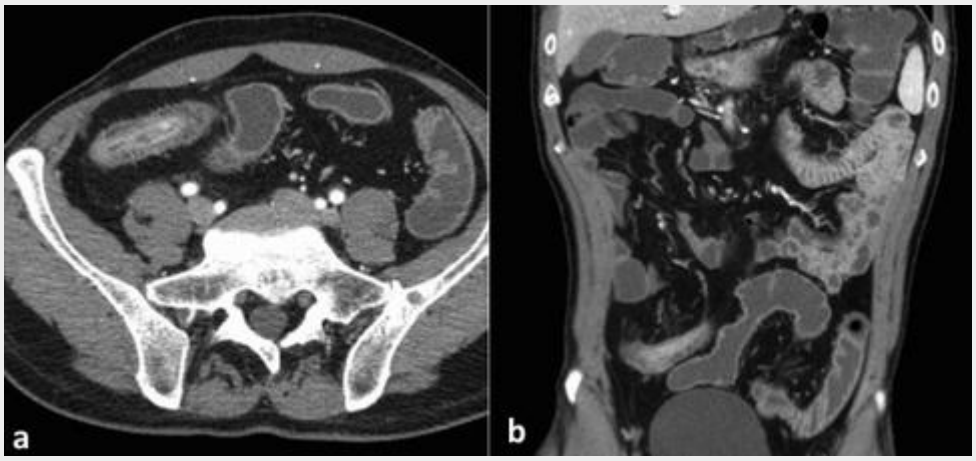

Crohn disease. Concentric parietal thickening of terminal ileum with trilaminar appearance (target sign) and engorgement of vasa recta (comb sign).

Fig. 7

Iliopsoas muscle abscess in a patient with terminal ileitis.

Infectious Enterocolitis

Infectious ileocolitis is a relatively common clinical condition that frequently presents with mild symptoms resembling those of viral gastroenteritis. However, symptoms may be indistinguishable from those of appendicitis when right lower quadrant pain is the major complaint, leading patients to seek medical

attention, mainly when the cause is infection of the ileocecal area by Yersinia enterocolitica, Campylobacter jejuni, and Salmonella enteritidis.

Imaging Findings:

· Circumferential wall thickening of the terminal ileum and cecum (usually with preservation of a layered enhancement pattern on CT);

· Absence of inflammation of the surrounding fat;

· Moderate or marked mesenteric adenopathy in the right lower quadrant.

Right Colonic and Cecal Diverticulitis

Diverticulitis of the colon is one of the most common causes of acute abdominal pain in elderly patients, predominantly affecting the left and sigmoid colon. Less often, the right colon and cecum may be involved, clinically mimicking appendicitis (Fig. 8 and 9). Sometimes, diverticulitis in a redundant sigmoid colon may also be mistaken for acute appendicitis (Fig. 10).

Imaging Findings:

· Asymmetric or circumferential colonic wall thickening associated with focal inflammatory changes of the pericolic fat (hyperechoic in sonography and fat stranding on CT);

· Demonstration of diverticula, with inflamed diverticula usually located at the level of maximum pericolic inflammation and maximum wall thickening;

· Wall thickening usually preserves wall enhancement pattern (inner high-attenuation layer, thickened low-attenuation middle layer, and outer high-attenuation layer);

· Fluid in the mesentery and engorgement of adjacent mesenteric vasculature.

The last two topics are the most discriminative findings favoring diverticulitis over right colic carcinoma (pericolic lymph nodes adjacent to the focal area wall thickening are more commonly seen in patients with malignancy than in those with diverticulitis).

Fig. 8

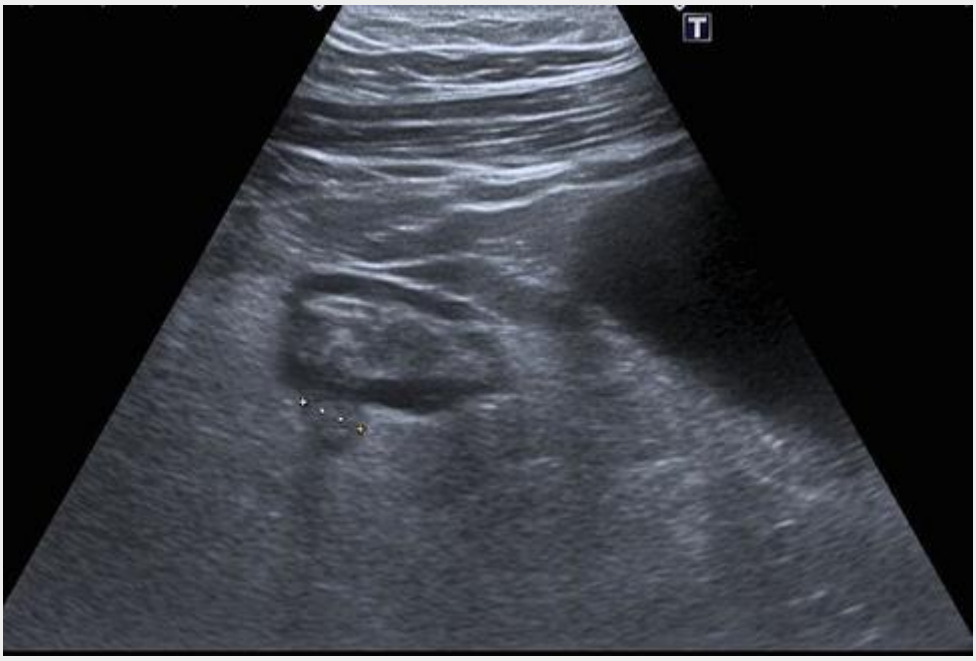

Diverticulitis – US shows colonic wall thickening with hyperechoic pericolic fat, and an inflamed diverticula was seen.

Fig. 9

Cecal Diverticulitis – in this case only pericolic fat stranding was seen, with a normal appendix (arrow).

Fig. 10

Sigmoid diverticulitis – redundant sigmoid, with a segment located in the right lower quadrant, showing colonic wall thickening and fat stranding. There are several colonic diverticula.

Right colonic neoplasia - Adenocarcinoma

Typically occur in elderly patients, who may present with rectal bleeding, anemia, low-grade fever, or a palpable mass.

Right colonic carcinoma may present with acute lower abdominal pain, usually due to obstruction or perforation. Although they may occupy a large proportion of the colic lumen, they rarely cause obstruction and often grow without clinical manifestations for long periods of time. Perforation in colon cancer occurs in up to 10% of cases and is more often a subacute process due to slow gradual infiltration of the bowel wall, masking inflammatory signs.

Imaging Findings:

· Marked asymmetric colonic wall thickening,

· Involvement of a short segment and abrupt change from a normal to an abnormal segment of colon suggest the diagnosis;

· Wall thickening is more severe relative to pericolic infiltration than in most acute inflammatory diseases, particularly diverticulitis;

· However, when perforation occurs, resulting in fat stranding, fluid collections and abscess formation, the diagnosis becomes more challenging and may mimic appendicitis;

· The distal ileum may be affected and abnormally thickened in up to 10% of cases (caused by tumor extension or, less commonly, by congestion and edema).

Epiploic Appendagitis

Acute epiploic appendagitis is a self-limited inflammation of the appendices epiploicae, which are are peritoneal pouches, composed of adipose tissue and blood vessels, that arise from the serosal surface of the colon, to which they are attached by a vascular stalk. Typically, the epiploic appendages are visible on CT images only when they are inflamed and/or surrounded by fluid.

Epiploic appendagitis is thought to occur as a result of spontaneous torsion, ischemia, or inflammation of an epiploic appendage, causing focal abdominal pain that simulates appendicitis when located in the right lower quadrant (although more frequent in the left lower quadrant) (Fig. 11).

Imaging Finding:

· An oval fatty lesion less than 5 cm in diameter (typical diameter range, 1.5–3.5 cm), adjacent to the anterior colonic wall, and surrounded by inflammatory changes;

· Hyperattenuating well-circumscribed rim surrounding the mass;

· Sometimes a high-attenuation central dot is seen (due to venous thrombosis or central areas of hemorrhage or fibrosis);

· The wall of the colon may be thickened but is most often normal.

Fig. 11

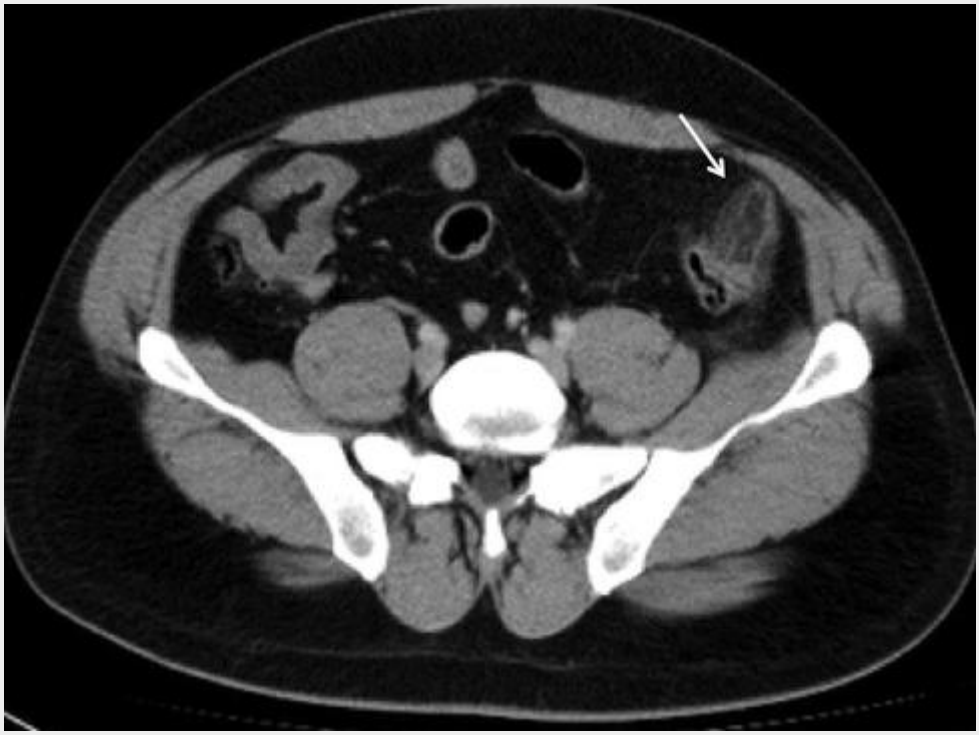

Epiploic appendagitis of the left colon. Oval fatty lesion adjacent to the anterior colonic wall surrounded by hyperattenuating well-circumscribed rim (arrow).

Omental Infarction

Omental infarction is a rare cause of acute abdomen, caused by interruption of blood supply to the omentum due to torsion or venous thrombosis.

It typically simulates acute appendicitis, with clinical features that include abdominal pain of a few days duration, most often localized in the right lower or upper quadrant. Unlike acute epiploic appendagitis, which predominantly affects adults, omental infarction occurs in a fair number of pediatric patients (approximately 15% of cases). Factors that predispose people to omental infarction include obesity, strenuous activity, congestive heart failure, digitalis administration, recent abdominal surgery and abdominal trauma.

Imaging Findings:

· Solitary, well-circumscribed, triangular or oval, heterogeneous nonenhancing fatty mass, sometimes with a whorled pattern of concentric linear fat stranding;

· Characteristically situated between the anterior abdominal wall and the transverse or ascending colon, correspondingin location to the greater omentum;

· Thickening of the adjacent bowel wall is either absent or disproportionally milder in comparison with the inflammatory changes in the omentum (unlike diverticulitis);

· CT appearance may resembles that of acute epiploic appendagitis, but it lacks the hyperattenuating ring seen in epiploic appendagitis and the lesion in omental infarction is larger and most commonly located next to the cecum or the ascending colon.

Pelvic inflammatory disease

Pelvic inflammatory disease (PID) refers to infection and resultant inflammation of the upper female genital tract, including the endometrium, fallopian tubes and ovaries. It is one of the most common diseases of women and can present with acute pelvic pain that may simulate appendicitis.

Risk factors include young age, multiple sex partners, high coital frequency, low socioeconomic status, douching and use of an intrauterine device (particularly during the first few months after insertion) as well as other forms of pelvic instrumentation.

Chronic sequelae include infertility, ectopic pregnancy and chronic pelvic pain and because of that it is important that this disease is diagnosed accurately and treated promptly.

PID is usually bilateral, except when it is caused by the direct extension of an adjacent inflammatory process such as appendiceal, diverticular, or post-surgical abscesses.

Imaging Findings:

The imaging findings vary according to the severity of the disease and may be normal in early conditions.

US:

· Ultrasound findings are often subtle and nonspecific and include mild enlargement or indistinctness of the uterus and ovaries;

· Increased echogenicity of the fat in the pelvis;

· Fluid in the endometrial canal and/or free fluid in the cul-de-sac;

· More specific US findings include: complex fluid collections, thickened fallopian tube wall >5mm, fluid filled fallopian tubes, and frank tubo-ovarian abscess.

CT:

· Early in the disease, the only clues can be edema in the pelvic fat planes, nonspecific free pelvic fluid, and fluid in the endometrial canal;

· Enlargement and increased number of ovarian follicles (the so-called "polycystic" appearance) is also considered a reliable finding of infection and inflammation;

· In more advanced cases, endometrial, ovarian and fallopian tube enhancement is seen;

· Later in the course of PID, the fallopian tubes exhibit an even greater degree of wall thickening and enhancement and fill with complex fluid, findings that usually indicate pyosalpinx;

· The extreme of the spectrum, as in US, is the presence of tubo-ovarian abscess (thick-walled, complex fluid collection that may contain internal septa, a fluid-debris level, or gas) (Fig. 12).

Fig. 12

Pelvic inflammatory disease - Tubo-ovarian abscess (thick-walled, complex fluid collection with internal septa). Free pelvic fluid is also seen.

Ruptured or Hemorrhagic Ovarian Cyst

The most commonly reported ruptured ovarian cysts are functional cysts, including corpus luteum cysts and follicular cysts, due to their increased vascularity. Endometriomas and dermoid cysts may also rupture,

but are less common. Rupture of a follicular or corpus luteum cyst may occur between days 20-26 of the menstrual cycle, or during the first trimester in pregnant women. A ruptured ovarian cyst most commonly occurs on the right side, and therefore may be difficult to distinguish from acute appendicitis.

Sudden onset, acute abdominal pain is the most frequent presenting symptom of a hemorrhagic or ruptured ovarian cyst.

Imaging Findings:

US:

· Cyst with internal echoes, with a fine, lacelike, reticular pattern (in the first 24 hours);

· As the thrombus coalesces, discrete, rounded, hyperechoic, avascular masses may be visualized at the cyst wall;

· Fluid-fluid or fluid-debris levels may be present within the cyst (as the clot liquefies);

· In the case of massive hemorrhage, free intraperitoneal fluid may be present, while the cyst itself may be collapsed.

CT:

· Before rupture presents as a high-attenuation adnexal mass on unenhanced CT (internal attenuation of 25–100 HU) (Fig. 13);

· Fluid-fluid levels and hemoperitoneum may be observed after cyst rupture.

Follow-up US may be performed within one or two menstrual cycles to determine whether the cyst has resolved.

Fig. 13

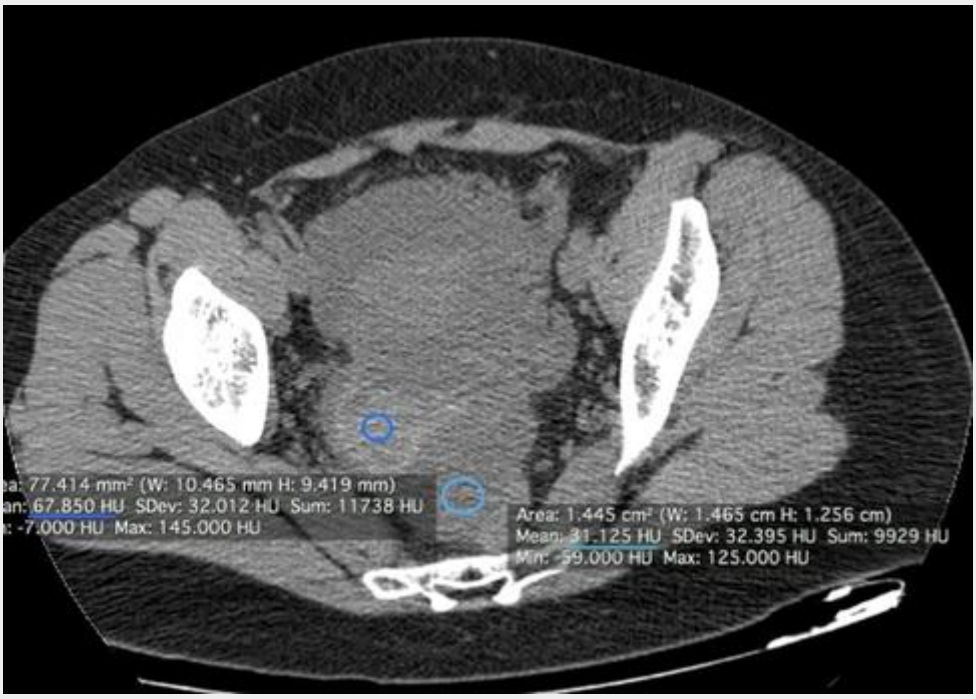

Ruptured Ovarian Cyst - High-attenuation right adnexal mass on unenhanced CT (~67 HU). Also high-density free fluid is seen, suggesting hemoperitoneum.

Ovarian torsion

Adnexal torsion occurs when the ovary, with the surrounding tissues, becomes twisted on its vascular pedicle. It generally occurs in the setting of a benign adnexal mass, although it also may occur in normal ovaries, most commonly in prepubertal girls. Risk factors include pregnancy, mainly at 8–16 weeks of gestation, due to rapid changes in uterine size and morphology. Pelvic pain may be intermittent or may resolve in the presence of partial or intermittent torsion. The prompt diagnosis of torsion is critical to allow conservative ovary-sparing surgical intervention in young women.

As the vascular pedicle twists, the venous and lymphatic system become occluded, which leads to an enlargement of the ovary (Fig. 14).

Imaging Findings

US:

· Enlargement of the ovary, with central hyperechogenicity (edema);

· Enlarged (up to 25 mm in diameter) nonovulatory follicles at the periphery;

· US images may depict the cyst (or, less commonly, the mass) that predisposed the ovary to torsion;

· As torsion progresses, hypoechoic regions are detected (hemorrhagic infarction);

· Free fluid also is frequently present, but this finding is nonspecific;

· A twisted vascular pedicle may be visualized, with swirling of the vasculature - whirlpool sign;

· Color Doppler may show an absence of arterial waveforms or high resistance to arterial flow with absent venous flow - highly suggestive of ovarian torsion, particularly when accompanied by ovarian enlargement;

· Doppler arterial waveforms may persist normal (as a result of ovary's dual arterial supply).

CT (accuracy inferior to that of US):

· Adnexal mass or enlarged ovary with a diameter of more than 5 cm may be suggestive of torsion;

· Smooth wall thickening to more than 3 mm in cystic adnexal masses;

· Ascites and uterine deviation toward the affected side;

· Lack of contrast enhancement, or hematoma (due to hemorrhagic infarction).

Fig. 14

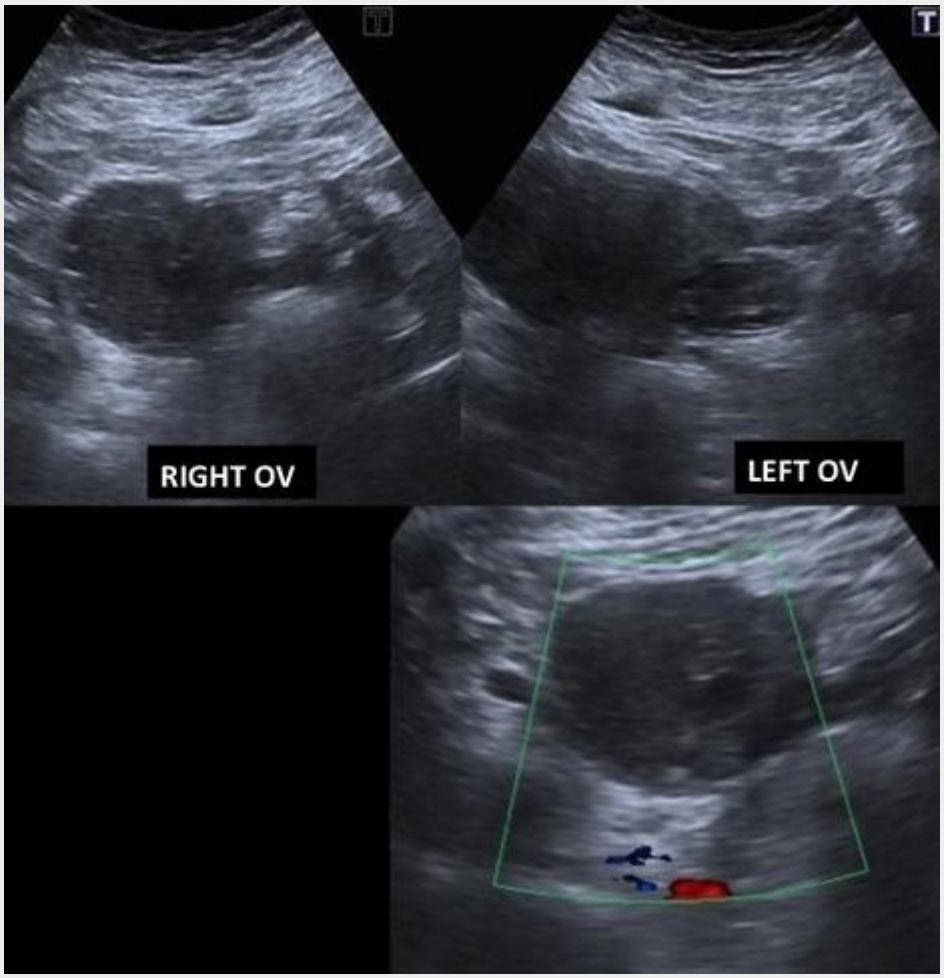

Ovarian torsion – US reveals Enlargement of the right ovary when compared to the left, with absent flow on Color Doppler. Laparoscopy was performed which confirmed ovarian torsion.

Ectopic pregnancy

Ectopic pregnancy is always a consideration in women of reproductive age with acute pelvic pain and with a positive B-hCG level. It usually occurs in isthmic or ampullary portion of fallopian tube (95-98%) and less often in interstitial portion (2-4 %). Risk factors for ectopic pregnancy are: previous tubal surgery, infertility treatment, tubal inflammation or past history of ectopic pregnancy.

The classic triad of ectopic pregnancy is abdominal pain, vaginal bleeding and adnexal mass.

Imaging Finding:

(Tubal Pregnancy – 95% of ectopic pregnancies)

US:

· Adnexal mass (most commonly located within the tube) showing hyperechoic rim and peripheral hypervascularity of the hyperechoic ring - "ring of fire" - on color Doppler (corresponding to increased flow within the trophoblastic tissue);

· Living embryo: 100% specific, but only seen in a minority of cases;

· Free fluid or haemoperitoneum;

· Intrauterine findings: normal endometrium, a pseudo-gestational sac (fluid collection within the endometrial cavity), a trilaminar endometrium, and a thin-walled decidual cyst;

· Ovary findings: corpus luteum cyst.

CT

· Intensely enhancing ring lesion in adnexal region which corresponds to the "ring of fire" appearance in US;

· In ruptured ectopic pregnancy - heterogeneous enhancing mass in adnexal region with associated haemoperitoneum.

Fig. 15

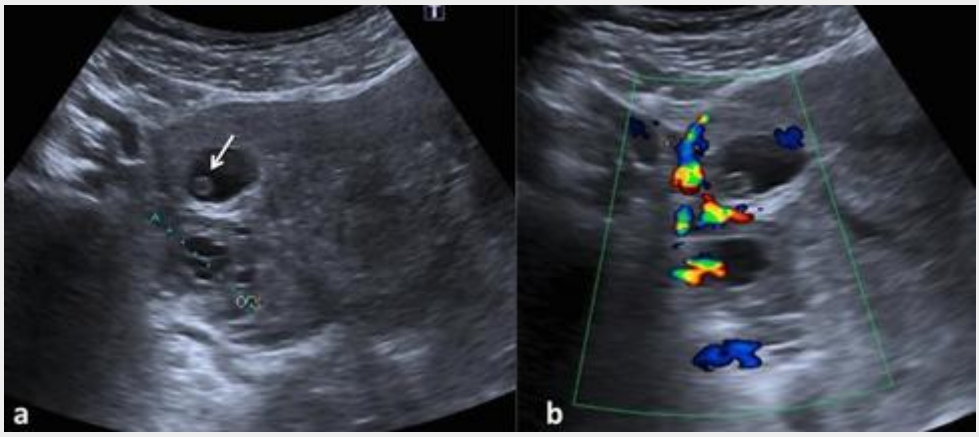

Ectopic pregnancy. Right adnexal mass, containing a gestational sac with fetal pole and yolk sac (arrow in a), showing peripheral hypervascularity (b).

Urolithiasis

Urolithiasis may present with right lower quadrant pain when obstruction is caused by a distal ureteral stone. Hematuria, although common, may be absent in ~15% of patients.

Unenhanced CT is more accurate in detecting ureteral stones than US, both often showing hydronephrosis and a hydroureter as signs of obstruction.

Imaging Findings:

US:

Ultrasound is frequently the first investigation of the renal tract, and although by no means as sensitive as CT, it is often able to identify calculi.

• *Hydronephrosis;*

• *Echogenic foci with acoustic shadowing (may not be present in smaller stones) in the ureter;*

• *"Twinkle" artifact on color Doppler.*

CT:

Virtually all stones are visible at unenhanced CT, including those that are radiolucent on conventional radiographs (uric acid, xanthine, and cystine stones); the only stones that are difficult to visualize at CT are pure matrix stones and stones made of indinavir (a protease inhibitor used in the treatment of HIV infection).

· *Stone within the ureteral lumen, with proximal ureteral dilatation and a normal distal caliber;*

· *Secondary signs: hydroureter, hydronephrosis, perinephric stranding, periureteral edema, and unilateral renal enlargement.*

Fig. 16

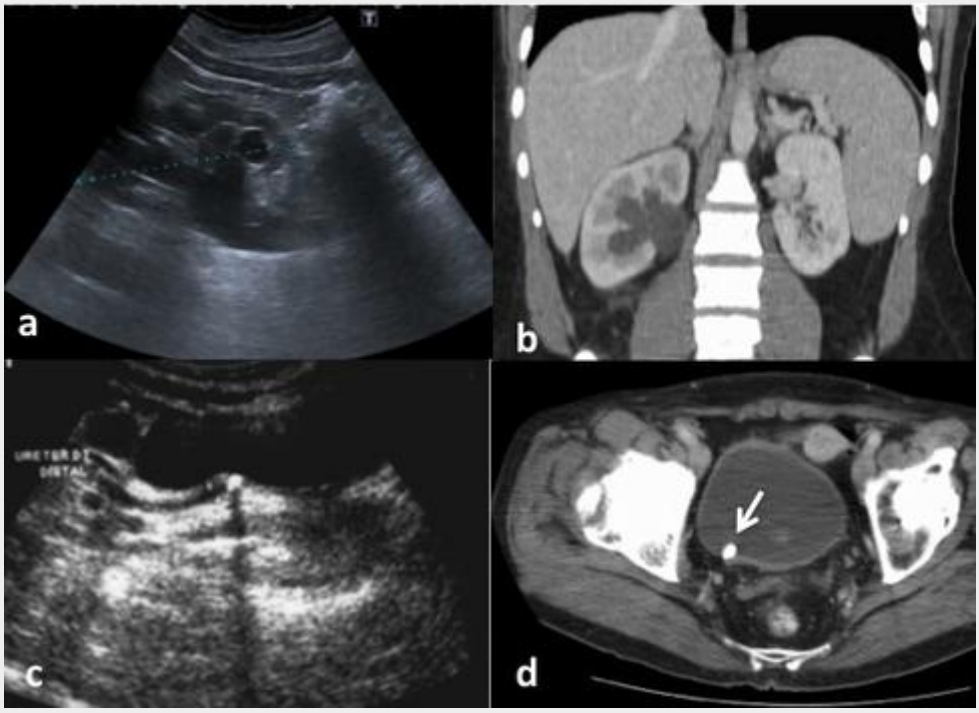

US (a) and CT (b) shows hydronephrosis of the right kidney. An obstructing stone in US (c) and CT (d) is seen in the vesicoureteric junction.

4. Conclusion

Right lower quadrant pain can be indicative of a vast list of differential diagnoses and is thus a challenge for clinicians. A correct imaging diagnosis of these alternative disorders may have a major impact on patient management, preventing unnecessary surgery and unwarranted hospital resource use.

5. References

1. Singh AK, Gervais DA, Hahn PF, Sagar P, Mueller PR, Novelline RA. Acute epiploic appendagitis and its mimics. Radiographics. 2005 Nov-Dec;25(6):1521-34.

2. van Breda Vriesman AC, Puylaert JB. Mimics of Appendicitis: Alternative Nonsurgical Diagnoses with Sonography and CT. AJR Am J Roentgenol. 2006 Apr; 186(4):1103-12

3. Kim HC, Yang DM, Jin W, Park SJ. Added Diagnostic Value of Multiplanar Reformation of Multidetector CT Data in Patients with Suspected Appendicitis. Radiographics. 2008 Mar-Apr;28(2):393-405; discussion 405-6. doi: 10.1148/rg.282075039.

4. Pereira JM, Sirlin CB, Pinto PS, Jeffrey RB, Stella DL, Casola G. Disproportionate Fat Stranding: A Helpful CT Sign in Patients with Acute Abdominal Pain. Radiographics. 2004 May-Jun;24(3):703-15.

5. Hoeffel C, Crema MD, Belkacem A, Azizi L, Lewin M, Arrivé L, Tubiana JM. MultiDetector Row CT: Spectrum of Diseases Involving the Ileocecal Area. Radiographics. 2006 Sep-Oct;26(5):1373-90.

6. Purysko AS, Remer EM, Filho HM, Bittencourt LK, Lima RV, Racy DJ. Beyond Appendicitis: Common and Uncommon Gastrointestinal Causes of Right Lower Quadrant Abdominal Pain at Multidetector CT.

Radiographics. 2011 Jul-Aug;31(4):927-47. doi: 10.1148/rg.314105065.

7. Sam JW, Jacobs JE, Birnbaum BA. Spectrum of CT Findings in Acute Pyogenic Pelvic Inflammatory Disease. Radiographics. 2002 Nov-Dec;22(6):1327-34.

8. Lin EP, Bhatt S, Dogra VS. Diagnostic Clues to Ectopic Pregnancy. Radiographics. 2008 Oct;28(6):1661-71. doi: 10.1148/rg.286085506.

9. Potter AW, Chandrasekhar CA. US and CT Evaluation of Acute Pelvic Pain of Gynecologic Origin in Nonpregnant Premenopausal Patients. Radiographics. 2008 Oct;28(6):1645-59. doi: 10.1148/rg.286085504.

6. Mediafiles

Fig. 1

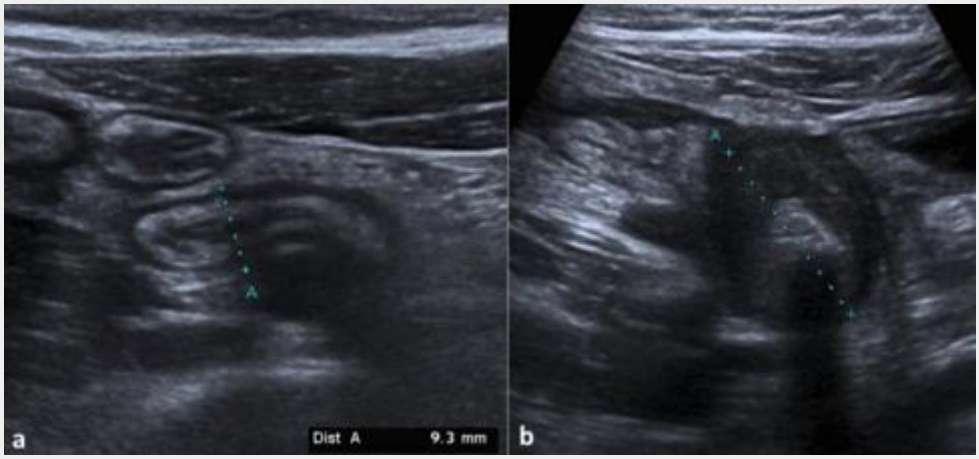

US images of an inflammed appendix. a) the appendix is distended, with parietal thickening and periappendicular fat is hyperechoic; b) intraluminal appendicolith.

Fig. 2

Thickened appendix with an intraluminal appendicolith

Fig. 3

Cecal thickening in a patient with appendicitis.

Fig. 4

CT showing a perforated appendix – a distended and thickened appendix, with periappendicular fat stranding and a collection surrounding its end.

Fig. 5

Mesenteric adenitis - CT of a young patient with RLQP showing severel mesenteric enlarged mesenteric lymph nodes, with no other identifiable inflammatory condition.

Fig. 6

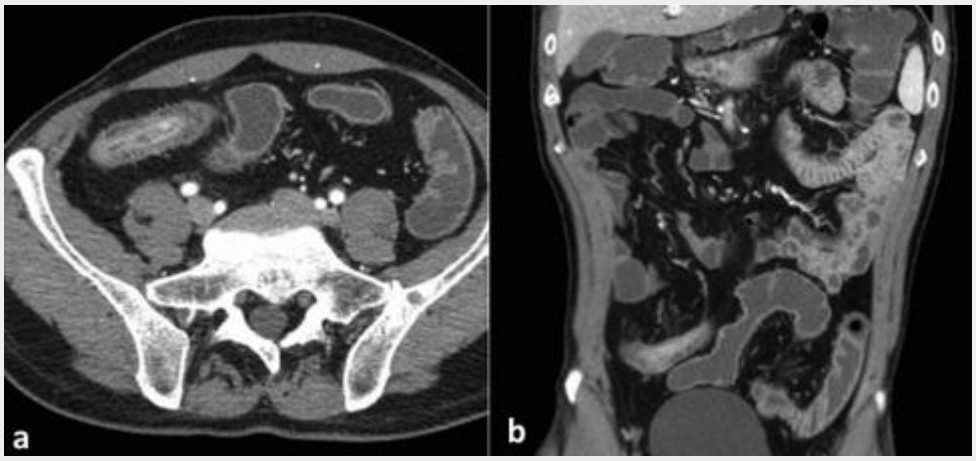

Crohn disease. Concentric parietal thickening of terminal ileum with trilaminar appearance (target sign) and engorgement of vasa recta (comb sign).

Fig. 7

Iliopsoas muscle abscess in a patient with terminal ileitis.

Fig. 8

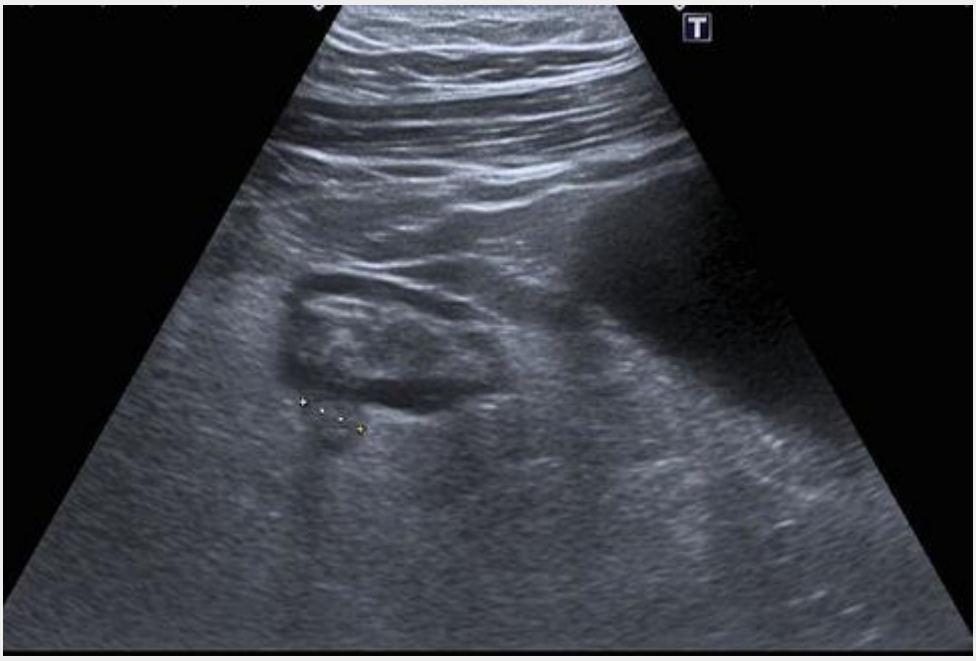

Diverticulitis – US shows colonic wall thickening with hyperechoic pericolic fat, and an inflamed diverticula was seen.

Fig. 9

Cecal Diverticulitis – in this case only pericolic fat stranding was seen, with a normal appendix (arrow).

Fig. 10

Sigmoid diverticulitis – redundant sigmoid, with a segment located in the right lower quadrant, showing colonic wall thickening and fat stranding. There are several colonic diverticula.

Fig. 11

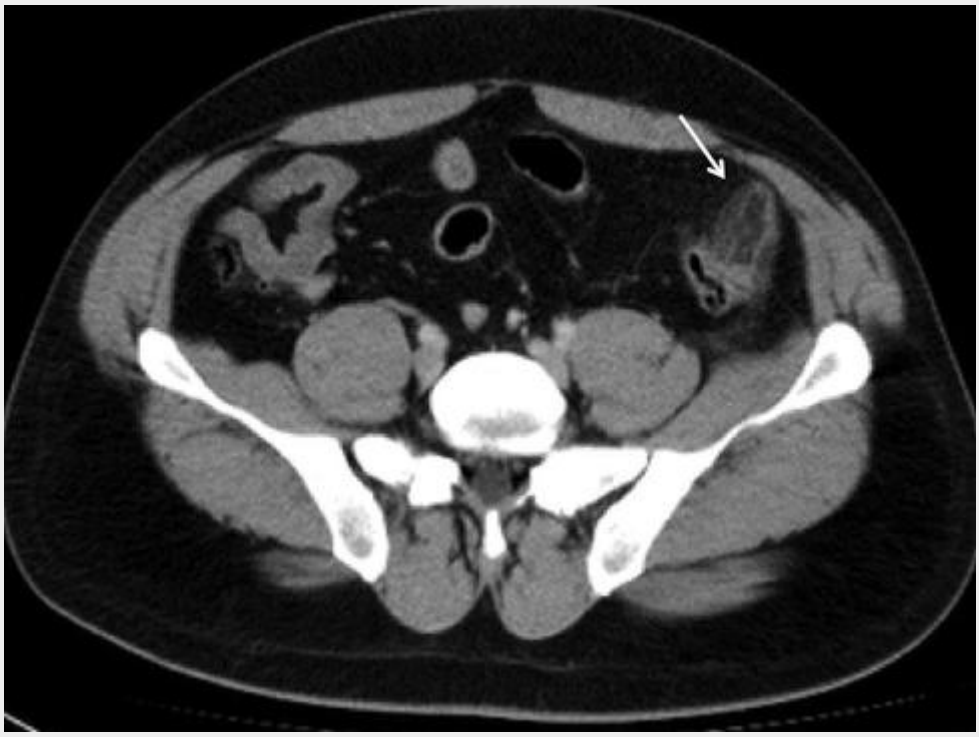

Epiploic appendagitis of the left colon. Oval fatty lesion adjacent to the anterior colonic wall surrounded by hyperattenuating well-circumscribed rim (arrow).

Fig. 12

Pelvic inflammatory disease - Tubo-ovarian abscess (thick-walled, complex fluid collection with internal septa). Free pelvic fluid is also seen.

Fig. 13

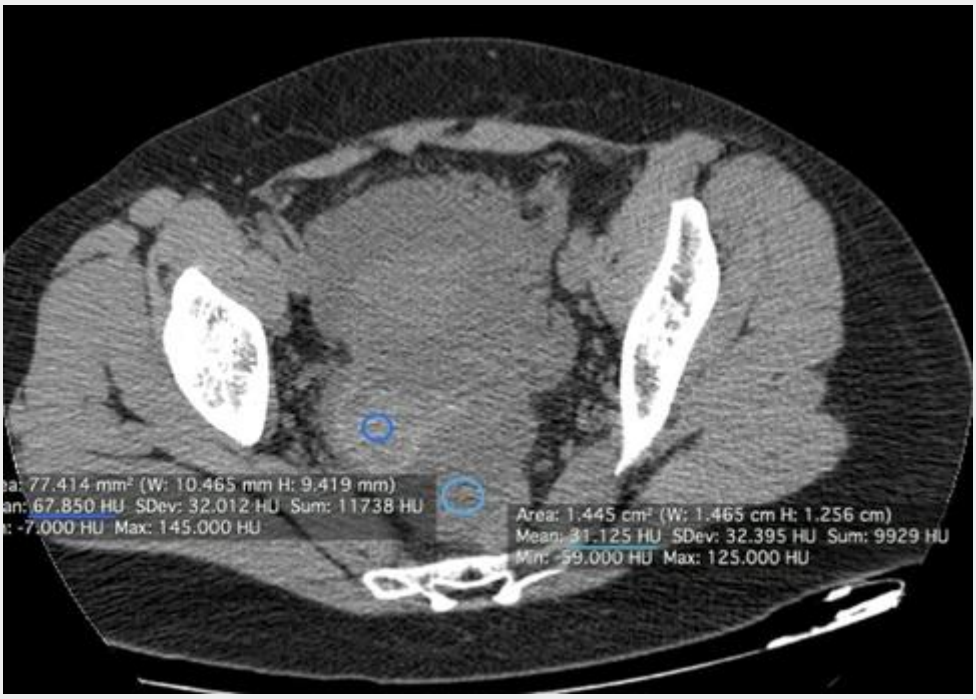

Ruptured Ovarian Cyst - High-attenuation right adnexal mass on unenhanced CT (~67 HU). Also high-density free fluid is seen, suggesting hemoperitoneum.

Fig. 14

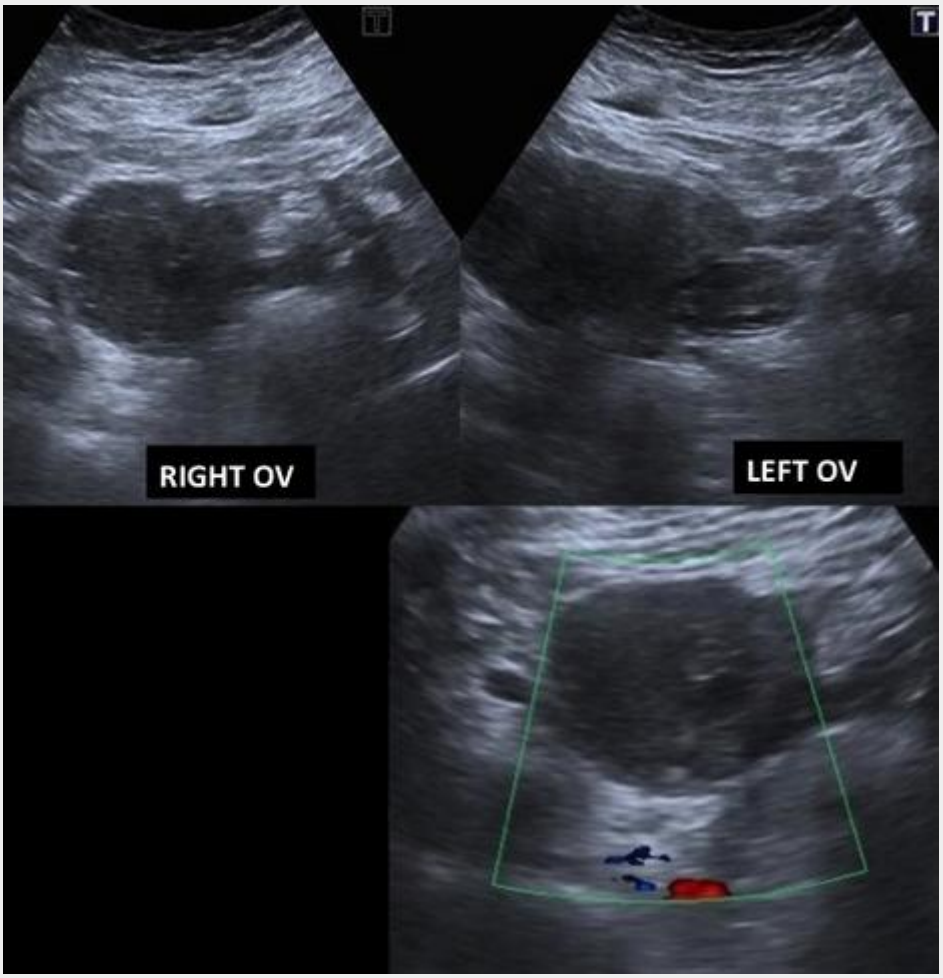

Ovarian torsion – US reveals Enlargement of the right ovary when compared to the left, with absent flow on Color Doppler. Laparoscopy was performed which confirmed ovarian torsion.

Fig. 15

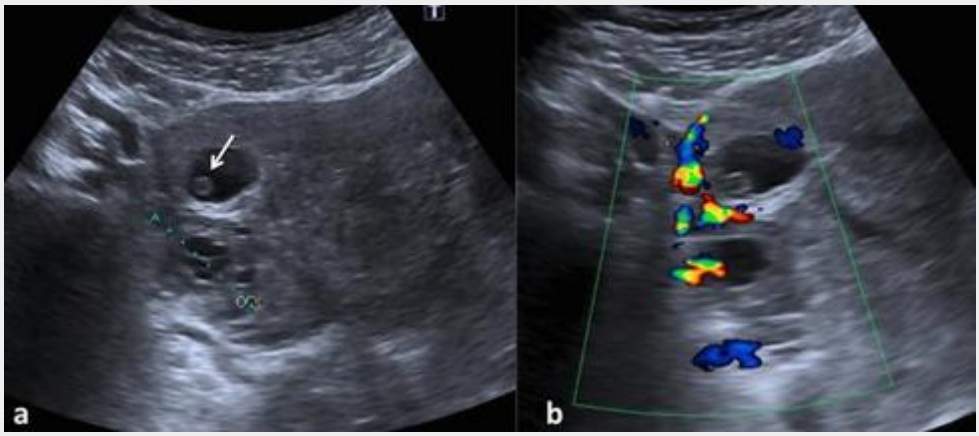

Ectopic pregnancy. Right adnexal mass, containing a gestational sac with fetal pole and yolk sac (arrow in a), showing peripheral hypervascularity (b).

Fig. 16

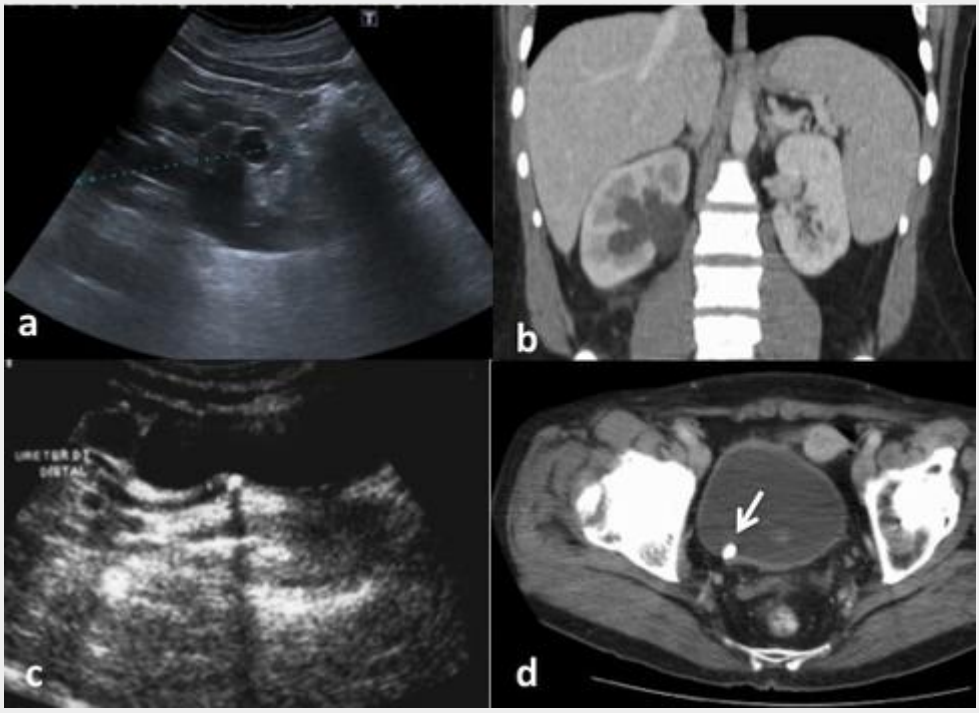

US (a) and CT (b) shows hydronephrosis of the right kidney. An obstructing stone in US (c) and CT (d) is seen in the vesicoureteric junction.